

Understanding the Boxer Bite

© Monique Hodgkinson 2009

The Boxer bite is a unique bite when compared to most other dogs' bites. Being a *brachycephalic* breed, there are some very obvious differences between the correct Boxer bite and the correct bite of a breed other than a *brachycephalic*. Many breed standards call for a scissor bite. This is an incorrect bite formation for a Boxer, which must be undershot. The Boxer Standard describes what the correct Boxer bite should be, but often it is difficult for people to understand and visualize what is meant. In an attempt to clarify this I have used the words of the Standard, photos of a correct Boxer bite and a description of what I understand the Standard to be asking for.

Muzzle: The muzzle is powerfully developed in three dimensional volume, neither pointed or narrow, nor short or shallow. Its appearance is influenced by:

a) Shape of jaw. b) Position of canine teeth. c) Shape of lips. The canines must be placed as far apart as possible and must be of good length, making the front of the muzzle broad, almost square and forming a blunt angle with bridge of nose.

In front, the edge of the upper lip rests on the edge of the lower lip.

This is vital, for if there is any deviation from this placement, there is an issue with the bite. If the lower lip protrudes past the upper lip the chances are that the dog is too undershot, and more than likely will show teeth or even tongue at some stage. If the upper lip 'hangs' over the lower lip the required undershot bite may be more of a reverse scissor bite than an undershot bite and the dog more than likely will lack chin, or repandous.

The part of the lower jaw with lower lip curved upwards, called the chin, must not markedly protrude over upper lip, seen from front. Nor should it be hidden by the lip but should be well defined from front and side.

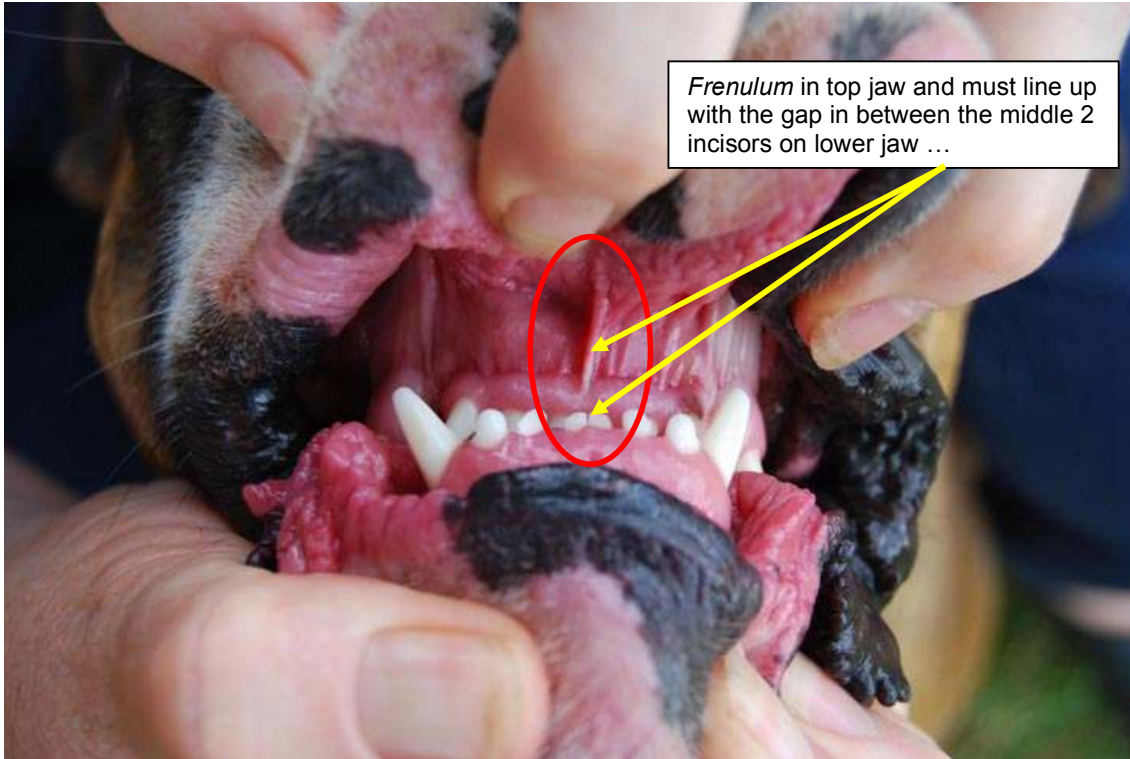
The chin of the Boxer is very important in imparting that typical Boxer look. While it must not be too obvious or too prominent, it must equally not be absent or so weak as to be virtually none existent. The standard says that the chin must be well defined from front and side. This means that you must see the chin when looking at the Boxer from the front as well as from the side of the head. A number of Boxers, when viewed from the side, have virtually no chin visible. This also affects the depth of the muzzle. If there is a lack of chin, the muzzle will appear shallow when viewed both from the front and the side.

The canines and incisors of the lower jaw must not be visible when mouth is closed, neither should the tongue show. Median groove in the upper lip (philtrum) is clearly visible.

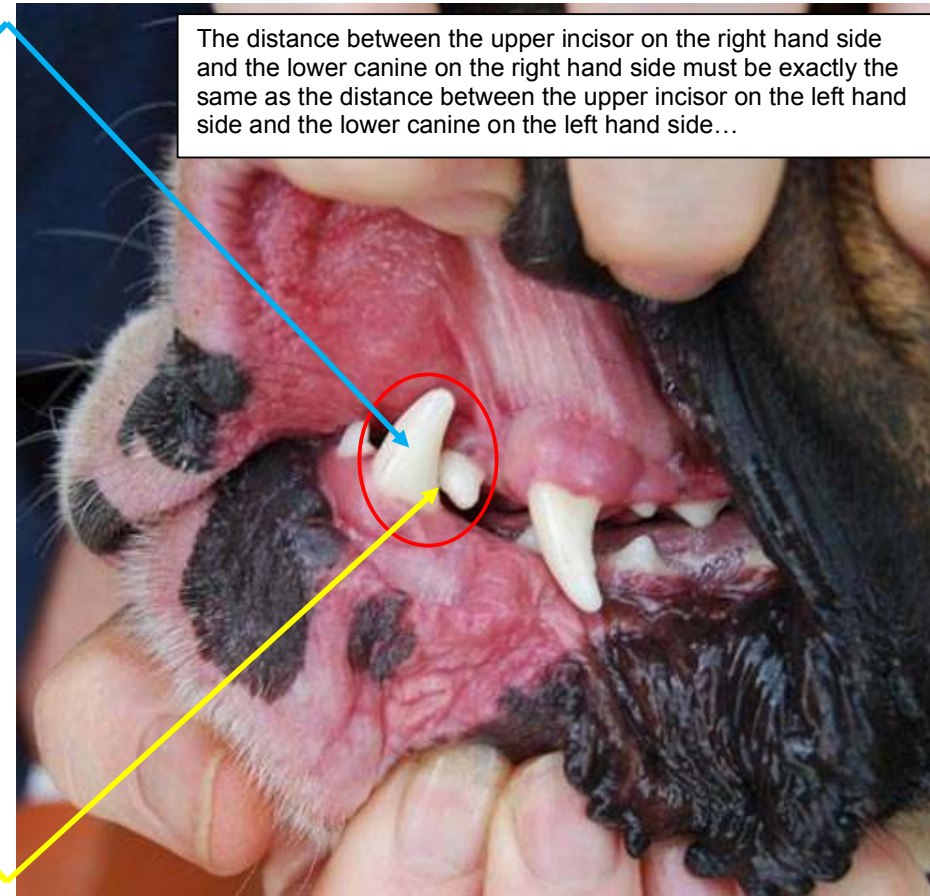
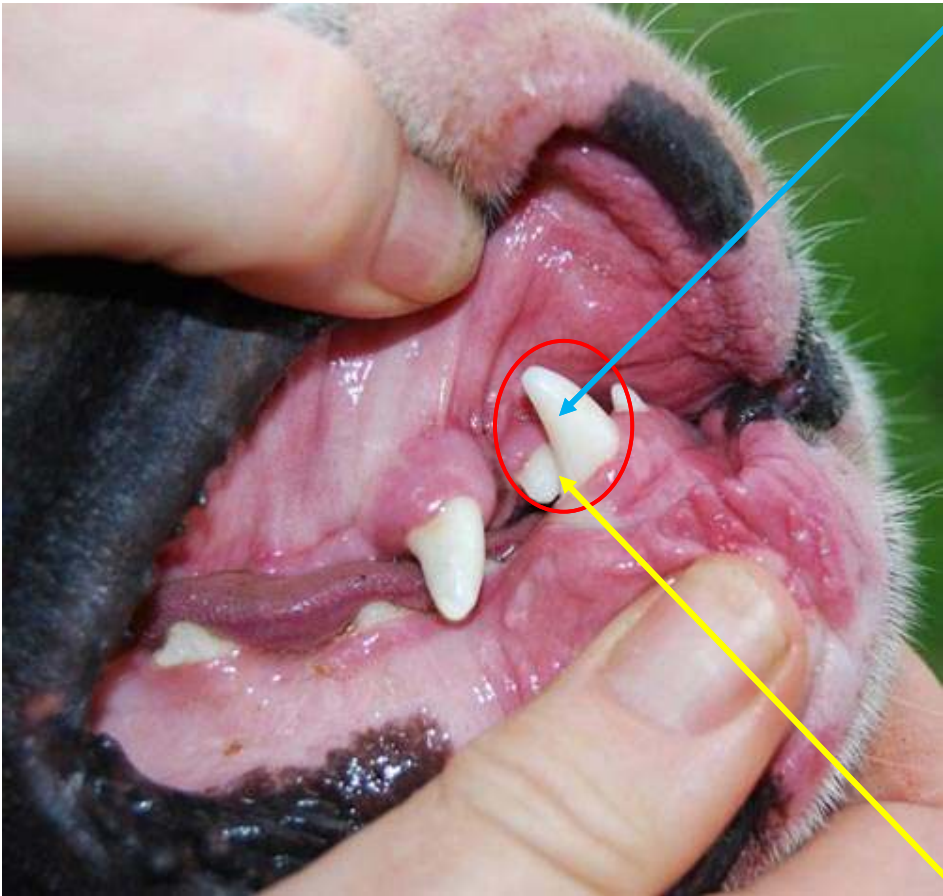
The median groove or *philtrum* is the line running from between the nostrils on the nose leather down to the edge of the upper lip. When viewed from the front, this line must be exactly in the middle of the upper jaw and a continuation of this line should pass through the centre of the lower jaw. When opening the mouth, the *frenulum* in the top jaw must line up exactly with the space between the central 2 incisors of the bottom jaw. Any deviation in this signals a wry, or off-centre bite. This is a very serious fault. The correctness of the bite of the Boxer should be determined by doing 5 things:

- a) Looking at the dog face-on, ensure that the *philtrum* runs straight through the middle of the chin;
- b) Lift the lips from the front and ensure that the *frenulum* in the top jaw lines up exactly with the gap between the middle 2 incisors of the bottom jaw;
- c) Lift the left lip and make sure that the outermost upper incisor sits just behind the rear edge of the lower left canine.

- d) Lift the right lip and make sure that the outermost upper incisor sits just behind the rear edge of the lower right canine.
- e) Compare the placement of the upper **right** incisor against the lower **right** canine with the placement of the upper **left** incisor against the lower **left** canine and ensure that there is the same amount of space on both sides.



The distance between the upper incisor on the right hand side and the lower canine on the right hand side must be exactly the same as the distance between the upper incisor on the left hand side and the lower canine on the left hand side...



Lips: The lips complete the shape of the muzzle. The upper lip is thick and padded and fills the space formed by the undershot lower jaw; it is supported by the lower canines.

The lip placement is very important as this is also used to determine, from the outside, whether the formation of the jaws, teeth and bite is correct. The upper lip should just rest on the lower lip, as shown below. The upper lip should also be well padded so that the space created by the lower jaw being undershot (and therefore protruding past the top jaw) is filled adequately.



Correct lip placement, with the upper lip resting on the lower lip



Top lip overhanging the bottom lip due, most likely, to the dog not being undershot enough.



Lower lip protruding past upper lip, often as a result of the lower jaw being too undershot

Jaws/Teeth: The lower jaw exceeds the upper jaw and is slightly curved upwards. The Boxer is undershot. The upper jaw is broad where it joins the cranial region, tapering only slightly towards the front. The teeth are strong and healthy. The incisors are as even as possible, set in a straight line. Canines wide apart and of good size.

The lower jaw should be curved slightly upwards so that when you look in the front of the Boxer's mouth, with the jaw closed, you should find that the upper teeth are hidden behind the lower jaw, due to this curve.

